

A STUDY ON THE OUTCOME OF TITANIUM ELASTIC NAIL FIXATION IN PAEDIATRIC LOWER LIMB LONG BONE FRACTURES

R. Anbalagan¹, T.P. Saravana Kumar¹, Loordusamy Chinthan², P. Naveenkumar²

¹Assistant Professor, Department of Orthopaedics, Government Medical College Hospital, Karur, Tamil Nadu, India.

²Junior Resident, Department of Orthopaedics, Government Medical College Hospital, Karur, Tamil Nadu, India.

Received : 05/02/2024
Received in revised form : 01/03/2024
Accepted : 16/03/2024

Keywords:

Outcome, Titanium Elastic Nail, Paediatric, Lower Limb Long Bone Fractures.

Corresponding Author:

Dr. P. Naveenkumar,
Email: navienortho@gmail.com

DOI: 10.47009/jamp.2024.6.2.114

Source of Support: Nil,
Conflict of Interest: None declared

Int J Acad Med Pharm
2024; 6 (2); 525-531



Abstract

Background: Paediatric long bone fractures of lower extremities are the most common major paediatric injuries treated by orthopaedic surgeons. The objective is to find out the clinical, radiological & functional outcome of paediatric long bone fractures in lower limbs treated with this new operative method, titanium elastic nailing. **Materials and Methods:** This study was conducted in the Department of Orthopaedic Surgery, Government Medical College Hospital, Karur during the period of July 2021 to October 2022. **Result:** The study was done on children between 5 – 17 yrs age group. Flexible titanium elastic nailing was performed on 15 children with 16 fractures. Out of the 16 cases 11 cases were done on femur and 5 cases were done on tibia. Among the 16 fractures 14 were simple fractures and 2 were compound fractures. Out of 16 fractures, open reduction and internal fixation was done for 5 cases (3 femoral fractures & 2 tibial fractures). Closed reduction and internal fixation was done for 11 cases (8 femoral fractures & 3 tibial fractures). The most common complication was skin irritation at the nail entry site which occurred in 4 cases. Out of the 4 cases, 1 case also developed superficial infection at the nail entry site. In our study there was no varus / valgus deformity. There was no mal-union or delayed union or non union or refracture in any of the cases. **Conclusion:** Titanium Elastic Nail can be used safely in lower limb long bone fractures in children with a good outcome without any major complications.

INTRODUCTION

The treatment of Paediatric long bone fractures of lower extremities include closed reduction with a hip spica casting with or without traction to operative treatment with intramedullary nails, plates and screws, and external fixators. Spica casting is effective in the treatment of children less than 6 years of age and the skeletally mature children is best managed with an antegrade interlocked intramedullary nail.^[1] The best treatment for children between the age group 6 and 16 years is still a matter of debate. This age group was traditionally managed by spica casting after a short period of traction. However, this method met with many complications and they also caused psychological, educational, social and economic problems.^[2]

Over the recent years, the advantages of fixation and early mobilization has been increasingly recognized. These included external fixation, plating, and nailing with solid intramedullary devices. Though

the long term results of the children treated by these methods have been excellent, still there are certain complications.^[3]

Metaizeau, Pre´vot, Ligier, and many others developed the elastic stable intramedullary nail in the 1980s. It was first developed in Nancy, a place in France. This brought a solution to those complications. After that, these elastic stable intramedullary nails (ESINs) are being refined in many ways.^[4]

ESIN ranks high as a conservative treatment in paediatric traumatology. It is now more commonly used for the treatment of paediatric long bones fractures. ESIN has reduced the surgical scarring caused by open reduction and plating. Titanium elastic nail achieves biomechanical stability from the divergent “C” configuration and this configuration creates six points of fixation and it allows the nail to act as an internal splint. The flexible titanium elastic nail provides stable and elastic fixation and this allows for a controlled movement at the fracture site which results in

healing by external callus. Several studies have been done to prove the safety and usefulness of this technique.^[5]

Our study attempts validate the use of one of the most recent advances in the treatment of pediatric long bone fractures, titanium elastic nailing (TEN). Though there are many recent studies describing the outcome of fractures treated with TEN and its complications, the purpose of this study is to find out the clinical, radiological & functional outcome of paediatric long bone fractures in lower limbs treated with this new operative method, titanium elastic nailing.

MATERIALS AND METHODS

This study was conducted in the Department of Orthopaedic Surgery, Karur Medical College Hospital, Karur during the period from July2021 to October2022.

Inclusion Criteria

1. Age: 5-17 yrs
2. Acute closed displaced/undisplaced diaphyseal fractures.
3. Acute Type I, Type II, Type IIIA open fractures
4. Closed comminuted fractures
5. Segmental fractures

Exclusion Criteria

1. Closed fractures more than 2 wks old
2. All open fractures presenting late with infection
3. Pathological fractures

The patients were analysed for their clinical, radiological and functional outcome and complications if any. For evaluation of these patients, limb-length discrepancy, limb alignment and rotation, callus formation, status of implant, quadriceps strength, the range of motion of the hip and knee, the condition of the wound and skin, and any pain or other symptoms were noted at each follow up visit. limb-length discrepancy was determined by physical examination. At each post operative visit, AP and Lateral X-Rays were taken and they were analysed. Nails were removed when the fracture line was not visible on X – Rays. This usually happened around 6 – 8 months after the surgery. The patients were assessed by Flynn's criteria.

Pre-Operative Assessment

1. Standard antero-posterior and lateral view x-ray of the involved limb.
2. Size of the nail is determined from the standard x-ray views.
3. Complete blood investigation

Principal of ten: Titanium elastic nailing is based on the principal of symmetrical bracing action of two nails inserted through the metaphysis which bears against the inner bone at three points. It provides flexural, axial, translational and rotational stability.

Properties of Nail

- Made of titanium alloy (Ti-6Al-7Nb) allowing dynamic loading at fracture site due to its flexibility.
- The tip of the nail is curved and flattened which penetrate the cancellous bone and provides axial and rotational stability.
- Available in length of 440mm and in diameter of 2, 2.5, 3, 3.5, 4 mm & they are colour coded for easy identification

Operative Technique

- Under general anaesthesia, the patient is positioned supine on a radiolucent table with the limb free or on a fracture table with a traction boot.
- Under fluoroscopy the fracture site and entry point are marked.
- The entry point for nail insertion is 2.5-3 cm proximal to distal physis for femur [Figure 1] and 1.5 - 2 cm distal to proximal physis for tibia [Figure 2].

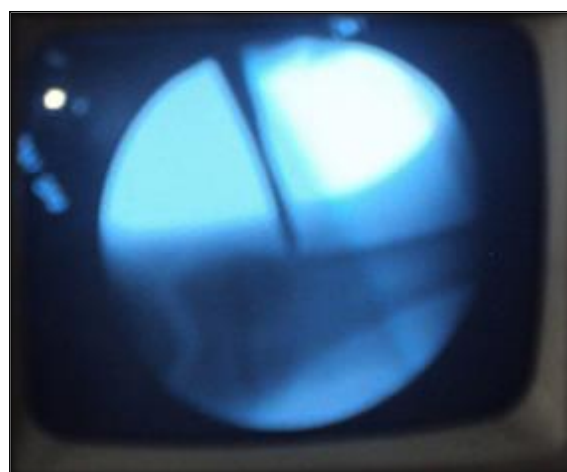


Figure 1: Femur nail entry site

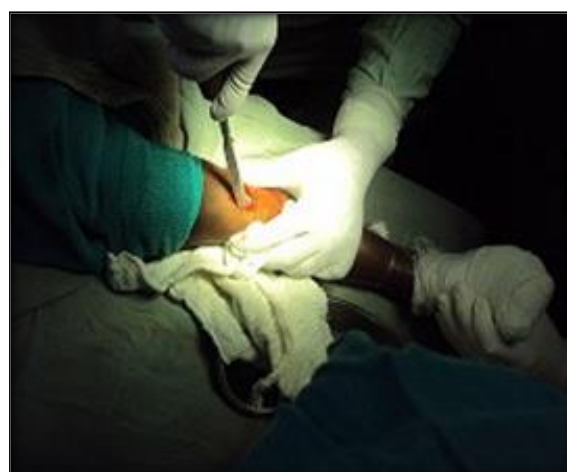

Figure 2: Tibia nail entry site

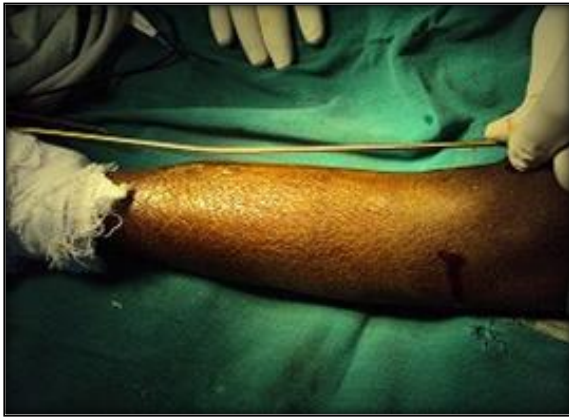

Figure 3: Contouring of nail

- A 2 cm longitudinal incision is made on both the medial and lateral side of metaphysis just proximal to the desired entry point.
- Appropriate sized implant is selected from pre-operative measurement. Nail diameter = 0.4 * narrowest canal diameter.
- Entry is made with an awl or with a drill 0.5 cm larger than the selected nail angling distally down the shaft facilitates nail entry
- The nails are pre-bent into a gentle “C” shape, with the apex at the level of fracture for three point fixation [Figure 3].
- Both nails are inserted and advanced to the level of fracture [Figure 4].

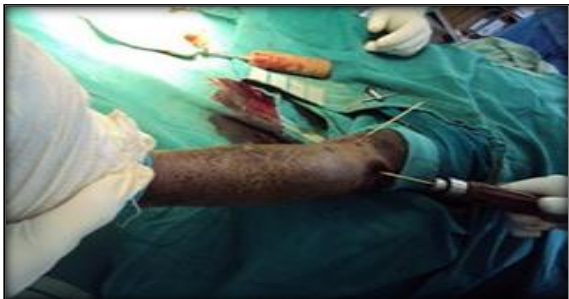

Figure 4: Nail insertion

- The fracture is reduced under fluoroscopic guidance in both the coronal and sagittal plane and the first nail is advanced through the fracture site [Figure 5].

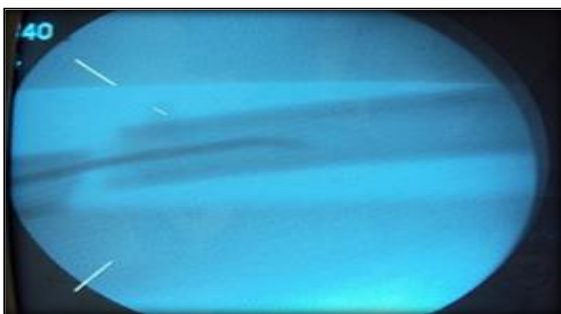


Figure 5: Reduction under fluoroscopy

- Intramedullary position of the nail distal to the fracture site is confirmed on AP and lateral

views and the second nail is tapped across the fracture site [Figure 6].

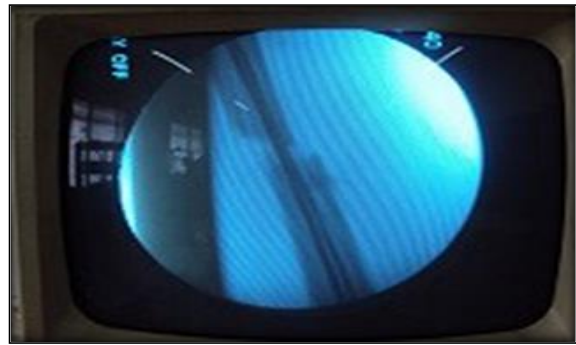


Figure 6: Nail passed under fluoroscopy

- Both the nails are advanced just proximal to the distal physis for tibia [Figure 7]

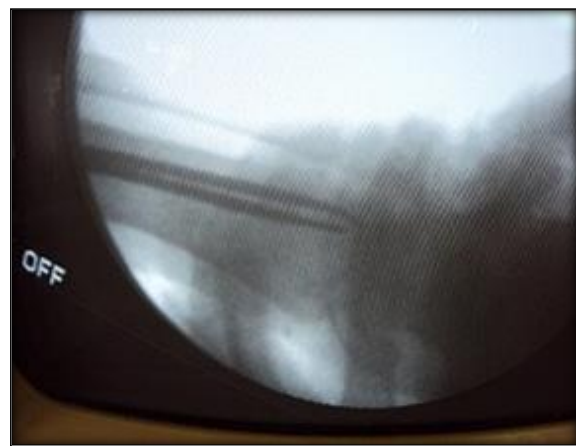

Figure 7: Distal level of nail in tibia

- In case of femur the nails are advance just distal to the trochanteric physis laterally and into the distal part of the neck medially [Figure 8].

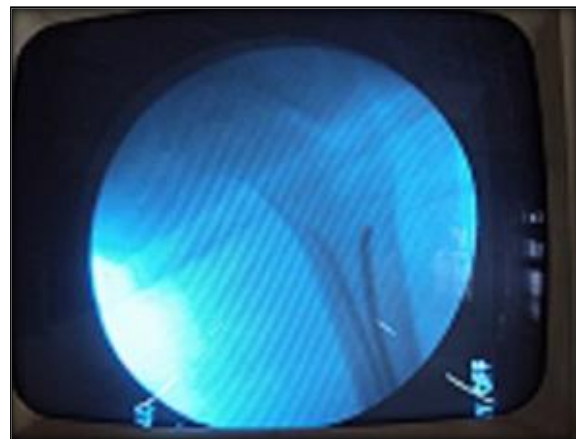


Figure 8: Proximal level of nail in femur

- Fracture reduction and nail position are confirmed fluoroscopically
- The proximal part of the nail is cut with the ends flushed and parallel to the metaphysis , 1 – 2 cm outside the medullary canal (fig ix).

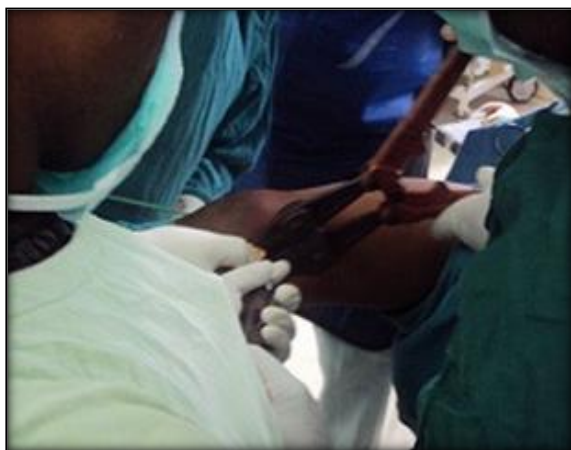

Figure 9: Cutting the nail end

- The incision for nail entry are closed in layers.
- Post operatively, the patients with unstable fractures are immobilized in hip spica cast for 3-4 weeks.

Post-Operative Follow-Up

- In stable fractures, immediate non weight bearing mobilization and knee bending is allowed after the pain subsides.
- Unstable fractures (spiral fractures, communitated fractures) are immobilized in hip spica cast for 3-4 weeks.
- Partial weight bearing is started at 4-8 weeks and full weight bearing at 8-12 weeks depending on the fracture configuration, callus response and associated injuries.
- Radiographic evaluation is done at 6 wks,12 wks and 24 wks.

RESULTS

Flexible titanium elastic nailing was performed on 15 children with 16 fractures. Out of the 16 cases 11

cases were done on femur and 5 cases were done on tibia. Among the 16 fractures 14 were simple fractures and 2 were compound fractures.

Out of 16 fractures, open reduction and internal fixation was done for 5 cases (3 femoral fractures & 2 tibial fractures). Closed reduction and internal fixation was done for 11 cases (8 femoral fractures & 3 tibial fractures).

The study was done on children between 5 – 17 yrs age group. The maximum age was 14 years and the minimum age was 5 years. The patients were followed for a period of 24 weeks. All the children were followed up and none of them missed follow up till 24 weeks.

Mode of Injury

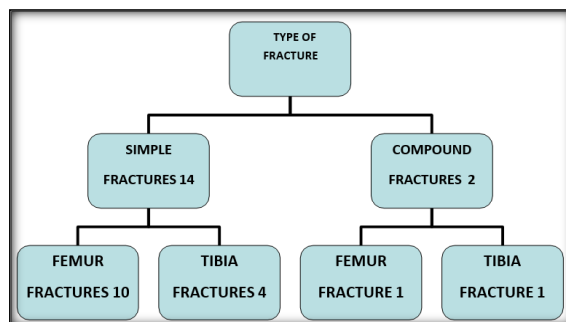
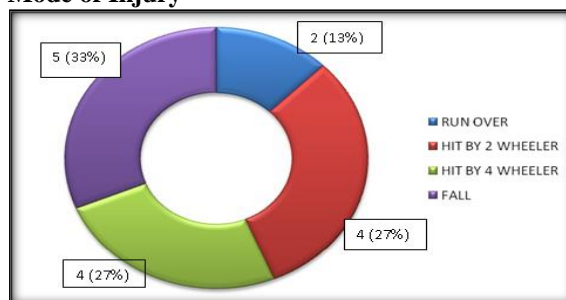


Table 1: TOTAL NUMBER OF FRACTURES

Total no of fractures	16
Femur	11(69%)
Tibia	5(31%)

Table 2: SURGICAL TECHNIQUE

Type of surgery	CRIF (closed reduction & internal fixation)	ORIF(open reduction & internal fixation)
FEMUR	8	3
TIBIA	3	2

Table 3: COMPLICATION

Serial Number	Complications	Number Of Patients
1.	Soft TissueIrritation ByHardware	4
2.	Varus/ValgusDeformity	---
3.	Limb LengthDiscrepancy	2 patients (corrected at24 weeks)
4.	Malalignment	---
5.	Non-Union	---
6.	Delayed Union	---
7.	Refracture	---

Table 4: OUTCOME ASSESSMENT BY FLYNNS' CRITERIA

Outcome	Excellent		Satisfactory		Poor
	No.	(%)	No.	(%)	
FEMUR	9	(82%)	2	(18%)	0
TIBIA	3	(60%)	2	(40%)	0

Table 5: TIME FOR FRACTURE UNION

Time (weeks)	No of fractures	Percentage
6-10	11	69 %
10-14	4	25 %
14-18	1	6 %
MEAN	9.3 WEEKS	

ANALYSIS

Average Fluoroscopy time	1 min 53 sec
Average operating time	1 hr 11 min
Mean time for complete radiological union	9.3 weeks
Mean time for partial weight bearing	6.8 weeks
Mean time for full weight weight bearing	10.6 weeks

Complications: The most common complication was skin irritation at the nail entry site which occurred in 4 cases. Out of the 4 cases, 1 case also developed superficial infection at the nail entry site. These children did not require nail removal until adequate fracture healing was achieved. The superficial infection was treated with i.v antibiotics and regular dressings. Subsequently the wound healed completely.

One case with skin irritation developed bursitis and knee stiffness. The knee stiffness improved from 30 deg of active knee flexion at 6 weeks to 100 deg of active knee flexion at 24 weeks.

The next common complication was limb length discrepancy, which was noticed in 2 cases. Both the case were operated for femoral shaft fractures. There was 1 cm shortening of limb in one case and 2 cm shortening in the other case.

The limb length variation got corrected at routine follow up at 24 weeks post operatively.

In our study there was no varus / valgus deformity. There was no malunion or delayed union or nonunion or refracture in any of the cases.

In our study, the operating time varied from a maximum of 98 min to a minimum of 50 min with an average operating time of 1 hour and 11 minutes. We also observed the fluoroscopy time for each case. The maximum fluoroscopy time was 139 seconds and the minimum was 92 seconds with an average fluoroscopy time of 1minute 53 seconds.

In our study, 12 children (75%) had excellent outcome and 4 children (25%) had satisfactory outcome. None of the children had poor outcome. This outcome analysis was done by Flynn's criteria. Out of the operated 11 femoral fractures, 9 children (82%) had excellent outcome and 2 children (18%) had satisfactory outcome. Out of the total 5 tibial fractures operated, 3 children (60%) had excellent outcome and 2 children (40%) had satisfactory outcome.

The time for partial weight bearing varied from a minimum of 4 weeks to a maximum of 9 weeks and the mean time for partial weight bearing was around 6.8 weeks

The time taken for full weight bearing ranged from 10 weeks to 16 weeks and the mean time taken for full weight bearing was 10.6 weeks.

The mean time taken for complete radiological union was 9.3 weeks. Radiological union occurred in 6 to 10 weeks in 11 cases (69%). In 4 cases(25%) radiological union occurred in 10-14 weeks and in 1 case (6%) radiological union occurred in 14-18 weeks.

The time for radiological union to occur was increased in case of comminuted fracture. There was no co-relation with age or weight of the children and fracture healing.

DISCUSSION

Flexible titanium elastic nailing is commonly used to treat long bone fractures in children between the ages of 5 and 17 years because it allows rapid mobilization with a few complications.^[6] Advantages of titanium elastic nail include rapid healing and bone remodeling without damage to physes.

Titanium elastic nail really is advantageous over other surgical methods particularly in the 6-16 yrs age group, because it is a simple, load-sharing internal splint that doesn't violate the physis. It also allows early mobilization and maintains alignment of the bone. Micromotion conferred by the elasticity of the titanium elastic nail promotes faster external bridging and callus formation. The periosteum is not disturbed and being done as a closed procedure there is no disturbance of the fracture hematoma & hence reduces the risk of infection.

The psychosocial and economic effects associated with spica casting and traction, and refracture risk, arthrofibrosis and pin tract complications associated with external fixation, treatment options have shifted towards the intramedullary devices for femoral shaft fractures.

Majority of tibial diaphyseal fractures in paediatric age group can be treated with closed reduction and casting. Very rarely operative stabilization may be required. External fixators has been preferred, but

the risks include non-union, refracture, pin tract infection. For the treatment of skeletally mature, reamed locked intramedullary nails have been shown to be effective, but it causes unnecessary risk to the proximal tibial physis, and has limited indications in growing children.

A prospective study done by Flynn et al showed that children treated with TEN achieve recovery milestones significantly faster than those children treated with traction and a cast.^[7]

The most common complication of femoral fractures in children is limb-length discrepancy. Gogi et al found that lengthening following TEN in children is a common phenomenon, but it gradually decreases and limb length symmetry is restored in the majority of children with the growth of the bone.^[8] Shortening is more important than lengthening and corrects slowly with time. In our study 2 patients had shortening but this shortening got corrected at the last follow up at 24 weeks.^[8]

The majority of TEN -related complications were associated with nail prominence and skin irritation at the entry site. Luhmann et al found that this complication can be minimized by using the largest possible nail diameter and leaving the segment of nail protruding from the bone less than 2.5 cm. For nail diameter sizing, the narrowest diameter of the femoral diaphysis was measured, and nails that were 40% of the narrowest diameter in size has to be used. Then, the extraosseous portion of the nails has to be cut such that 1-2 cm remains outside the cortex and also the nail has to be bent slightly away from the bone so as to prevent soft tissue irritation.^[9]

In our study, 4 children developed skin irritation at the entry site. But none of these children required premature removal of the nail before fracture union has occurred. One child developed superficial infection which healed with antibiotics. But they did not develop deep infections like osteomyelitis.

Immobilization of the affected limb with a spica cast for 3 to 4 weeks is usually recommended as this limits pain, supports the leg when the quadriceps is weakest and it also decreases the amount of nail-tip soft-tissue irritation. Certain studies have concluded that further immobilization with the hip spica cast is not necessary after elastic nailing when stable fixation has been achieved. In our study we have immobilized the limb for three to four weeks after titanium elastic nailing in children with unstable fractures, for additional stability. It is also believed that it was effective in preventing the complications such as implant failure during the early postoperative period.

TEN provides stability with the three-points principle, and the elasticity and stress distribution of nails encourages early callus formation. Engaging the nails more proximally to prevent the rotation and angulation decreases the force at the fracture site and maintains fracture stability. There were no patients with nonunion, malunion or angulation of the injured limb in either group.

Fluoroscopy has become an important tool in most of the orthopedic surgery. The development of minimally invasive surgical procedures further has increased the use of fluoroscopy. It has got several advantages, such as the preservation of soft tissues and blood supply, thereby reducing direct perioperative morbidity.^[1] Like other intramedullary fixation techniques, titanium elastic nailing also requires an increased amount of fluoroscopy time during the procedure.

Several studies suggest that when the surgical procedure is prolonged, the operating surgeons should change their surgical technique from closed reduction to open reduction to protect the patient from intra-operative radiation exposure.

O'Brien et al. reported a series of sixteen children with tibial shaft fractures. They were treated with TEN, and followed for a period of 17 months. All children in this series had radiographic union by an average of 9 weeks. At final follow-up none of them had angular deformity of more than 10 degrees and there was no significant limb length discrepancy.^[3]

Goodwin et al. followed 19 patients with tibial shaft fractures treated with TEN. All children had achieved union during the follow up period. 2 patients had angular deformities more than 10°, and 1 child had developed a clinically insignificant physeal arrest.³

The greater comfort of postoperative immobilization in tibial fractures, compared with that of the femoral fractures allows adequate maintenance of reduction in over-weight patients.

CONCLUSION

Use of Titanium Elastic Nail for lower limb fractures in children is a reliable, minimally invasive, and physeal-protective treatment method. Advantages of TEN include lesser duration of hospital stay, increased fracture stability and early return to normal activity. Complications are minor and do not produce any permanent disability. Our study showed that there were no major complications in any of these children. Hence Titanium Elastic Nail can be used safely in lower limb long bone fractures in children with a good outcome without any major complications.

REFERENCES

1. Fischer LP, Fessy MH, Bejui J et al. Ollier: the father of bone and joint and of reconstructive surgery
2. Kuntscher GB. The Kuntscher method of intramedullary fixation. *J Bone Joint Surgery* 1958;40-A: 17-26
3. Rockwood and Wilkins' fractures in children, 7th edition Lippincott Williams & Wilkins: 2010: pg 797-841
4. Flynn JM, Hersko T, Reynolds RA, et al. Titanium elastic nails for paediatric femur fractures: a multicentre study of early results with analysis of complications. *J Pediatric Orthop* 2002; 25: 1067-70
5. Narayanan UG. Elastic stable (flexible) intramedullary nailing of paediatric femur fractures. *COA Bulletin* 2003 www.coacoa.org/articles/Publications/Scientific.

6. Flynn JM, Skaggs DL, Sponseller PD, Ganley TJ, Kay RM, Kellie Leitch KK. The operative management of pediatric fractures of the lower extremity. *J Bone Joint Surg Am.* 2002;84:2288-300.
7. Flynn JM, Luedtke LM, Theodore J, Ganley TJ, Dawson J, Davidson RS, et al. Comparison of titanium elastic nails with traction and a spica cast to treat femoral fractures in children. *J Bone Joint Surg Am.* 2004;86:770-7.
8. Titanium elastic nails for paediatric femur fractures :clinical & radiological study. *Surgical science* 2010,1,15-19, Nishikant kumar , Laljee Chaudhary
9. Mini-open versus close reduction in titanium elastic nailing of pediatric femoral shaft fractures-A comparative study. *Acta Orthop.,Belg.,*2011,77, 211-217.Mehmet Akif Altay, Cemil Erturk, Hasan Cece, Ugur Erdem Isikan.